



Revista Agrária Acadêmica

[Agrarian Academic Journal](#)

Volume 3 – Número 1 – Jan/Fev (2020)



doi: 10.32406/v3n12020/26-33/agrariacad

Tomographic and histopathologic evaluation of an aseptic intra-abdominal gossypiboma in a dog: case report. Avaliação tomográfica e histopatológica do gossipiboma asséptico intra-abdominal em canino: relato de caso.

[Lourival Barros de Sousa Brito Pereira](#)^{1*}, [Gabriella Mignac Mendonça Brito](#)², Melissa Barbosa Pontes³, Gabriel Fernando Couceiro Viana², Magda Maria de Abreu Silva², Lucas Marinho Neves², Flávia Castilho Nolasco de Souza¹, Homero Firmo Pessoa¹

^{1*} Médico Veterinário Autônomo, Recife, Pernambuco, Brasil. E-mail: lorinho2013.1@hotmail.com

² Centro Universitário Maurício de Nassau – UNINASSAU, Recife, Pernambuco, Brasil.

³ Centro Universitário Brasileiro – UNIBRA, Recife, Pernambuco, Brasil.

Abstract

Gossypiboma is a term used for the inflammatory reaction caused by material, usually textile material, forgotten inside the abdominal cavity after a surgical procedure. The present objective was to report the case of a dog diagnosed with aseptic intra-abdominal gossypiboma and evaluate computed tomography and histopathology as complementary tools for surgical planning and definitive diagnosis. The animal in question was a 2-year-old mixed-breed dog with apathy two months after undergoing an ovariectomy. A computed tomography examination was performed, which helped with good surgical planning, and histopathology provided a definitive diagnosis.

Keywords: Cirurgia. Corpo estranho. Exame complementar.

Resumo

Gossipiboma é um termo utilizado para a reação inflamatória causada por material, geralmente têxtil, esquecido dentro da cavidade abdominal pós-procedimento cirúrgico. Objetiva com este trabalho relatar um caso de um canino diagnosticado com gossipiboma asséptico intra-abdominal e avaliar o exame de tomografia computadorizada e histopatologia como ferramenta complementar para um planejamento cirúrgico e diagnóstico definitivo. O animal em questão era um sem raça definida, com 2 anos de idade que apresentava quadro de apatia dois meses após ser submetida a um procedimento de ovari-histerectomia. Foi realizado exame de tomografia computadorizada que resultou em um bom planejamento cirúrgico e a avaliação histopatológica que propiciou um diagnóstico definitivo.

Palavras-chave: Surgery. Foreign body. Complementary examination.

Introduction

Veterinarians can make mistakes during the practice of their profession and are subject to the punishments inflicted by the Council of Veterinary Medicine. Emotional damages resulting from a veterinarian's mistake are a reflection of the emotional link between a person and their pets, where the loss of one of these companion animals may turn into psychological trauma. It is paramount that the veterinarian plan ahead by creating a file for each patient, to have evidence in the form of documents in case of lawsuits (MARQUES et al., 2014).

In human medicine, it is common to detect the presence of an intracavitary foreign body, usually of textile origin, forgotten inside the abdominal cavity after a surgical procedure. The material forgotten within the abdominal cavity causes a granulomatous inflammatory reaction called gossypiboma (CAVENAGO et al., 2015; OLIVEIRA R, et al., 2019), textiloma, or gauzoma (DESCHAMPS; ROUX, 2009; SILVA; SOUSA, 2013).

A gossypiboma may develop aseptically or as part of an exudative process. The aseptic form is the one that leads to adhesion and encapsulation, and the patient may remain asymptomatic for years. The exudative form leads to formation of an abscess and fistulae involving cavitory organs or the abdominal wall (CAVENAGO et al., 2015; DESCHAMPS; ROUX, 2009; OLIVEIRA et al., 2019).

There are few reports of this nature in veterinary medicine (AUGER et al., 2019). Differentials may include abscess, neoplasia, metastasis, or hematoma, which makes for a challenging diagnosis (OLIVEIRA et al., 2019).

In human medicine, a diagnosis of gossypiboma is based on clinical suspicion associated with imaging findings and in many cases, are only discovered during surgery (SILVA; SOUSA, 2013).

The radiographic diagnosis of gossypiboma is challenging due to its variable presentation (NETO et al., 2012). If the forgotten material within the abdominal cavity contains radiopaque markers, radiopaque lines or tape may be seen on radiographs. An abdominal ultrasound may be useful; however, it has a low sensitivity (SILVA; SOUSA, 2013).

Computed tomography is the complementary exam of choice for the diagnosis and evaluation of a gossypiboma, as it provides detailed information on the lesion. (AUGER et al., 2019; SILVA; SOUSA, 2013).

As such, the present objective was to report the case of a dog diagnosed with intra-abdominal aseptic gossypiboma and to evaluate the use of computed tomography and histopathology as complementary tools for surgical planning and a definitive diagnosis.

Material and methods

A dog presented with apathy to a veterinary clinic in the Graças neighborhood, in the city of Recife-PE. The dog was a 2-year-old mixed-breed domiciled female, with a diet basically of Super Premium dog food, and up-to-date vaccinations. Two months prior to presentation, she had undergone ovariohysterectomy and had an uneventful post-operative recovery.

On physical examination, the patient showed apathy, hyperemia of ocular and oral mucosae, capillary refill time of 4 seconds, thin body score, and rectal temperature of 38°C. On abdominal palpation, abdominal tension was noted and there was an uncommon intra-abdominal structure near

the topography of the spleen which had a circumscribed shape, and was encapsulated, mobile, and soft in consistency.

Routine exams were performed, such as hemogram, renal and hepatic panels, and abdominal ultrasound. The results led to suspicions of an intra-abdominal gossypiboma, with a differential diagnosis of neoplasia. Because surgery was needed, computed tomography was requested for better surgical planning.

On the day of the surgery for removal of the intra-abdominal loose mass, pre-anesthetic medication was done with an association of acepromazine 0.02mg/Kg (Acepran® 0.2%) and tramadol 4mg/Kg (Tramadol 50mg/mL), given intramuscularly. Induction was done using propofol 2mg/Kg (Propofol 10mg/mL) given intravenously, and maintenance with isoflurane given via endotracheal tube.

Following access to the abdominal cavity, it was possible to observe an encapsulated structure covered by the omentum. The structure was removed without complications, placed in 10% formalin, and sent for histopathological evaluation.

Results

The patient from the present report presented with apathy and weight loss. Hemogram and renal and hepatic panel results were within normal limits. On abdominal ultrasound, a loose mass near the stomach and splenomegaly were observed.

Computed tomography revealed the presence of a heterogeneous mass, with radiographic attenuation of approximately 53 Hounsfield units, located in the caudal abdominal region, approximately 2.5 cm cranial to the bladder (Figure 1).

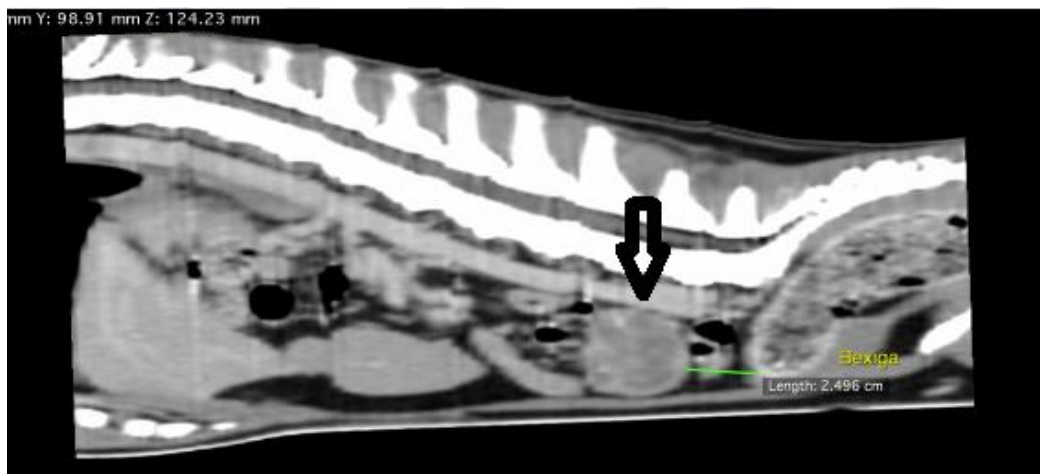


Figure 1. Computed tomographic image of a 2-year-old dog diagnosed with gossypiboma. The image shows a mass (arrow) within the abdominal cavity, cranial to the bladder.

The mass had a regular shape and encapsulated aspect and did not show signs of being adhered to adjacent organs or vascular structures or of peritonitis on computed tomography. Dimensions were approximately 4.56 centimeters in length x 3.03 centimeters in height x 5.0 centimeters in width (Figures 2 and 3).

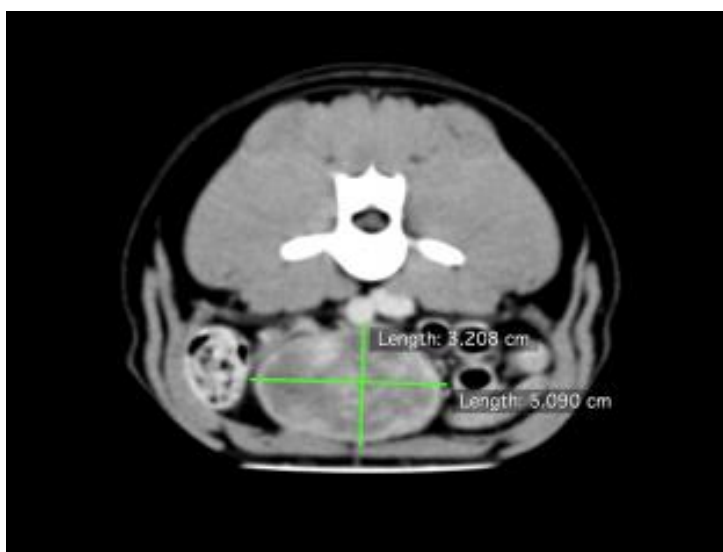


Figure 2. Computed tomographic image of a 2-year-old dog diagnosed with gossypiboma. The image shows suggested height and length measurements of the intra-abdominal mass on transverse slice.

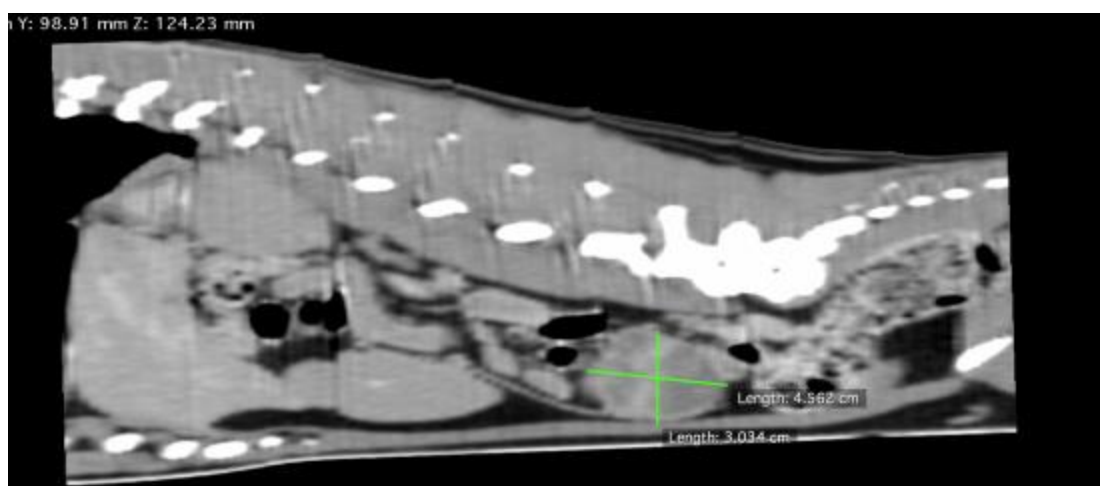


Figure 3. Computed tomographic image of a 2-year-old dog diagnosed with gossypiboma. The image shows suggested measurements of length and height on sagittal slice.

There was moderate contrast enhancement with intravenous iodine-based contrast medium (77 Hounsfield units), and also presence of hypoattenuating areas suggestive of tissue necrosis and areas of mineralization (Figure 4). Computed tomography findings suggested a neoplastic process, but no organ of origin was identified.

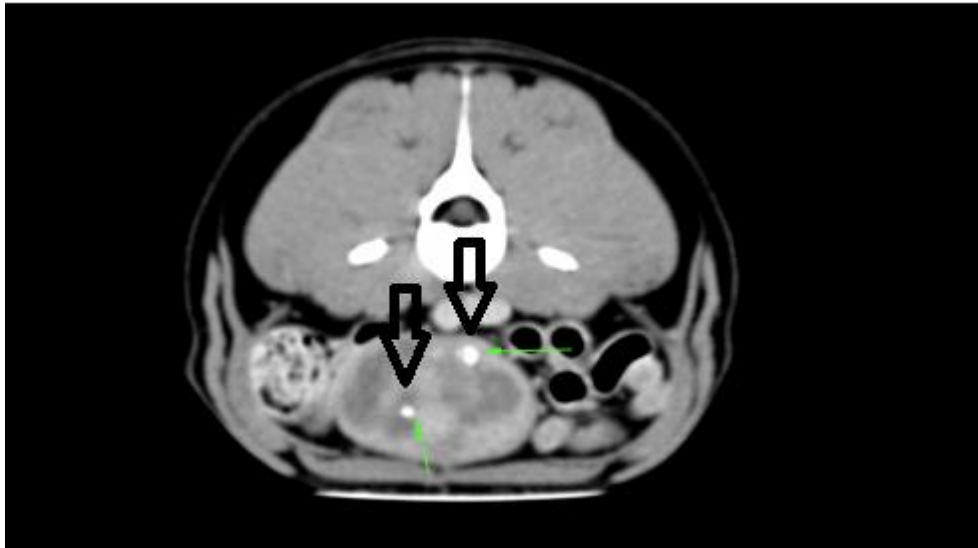


Figure 4. Computed tomographic image of a 2-year-old dog diagnosed with gossypiboma. The image shows areas of mineralization (arrow) and tissue necrosis.

The liver was increased in size, but homogeneous and without nodular lesions or signs of metastatic dissemination. The spleen was significantly increased in size. Intra-abdominal lymph nodes were normal in size, the urinary system was normal before and after administration of the contrast, the gastrointestinal tract and pancreas were also within normal limits, and there was no intra-abdominal free fluid (Figure 5).

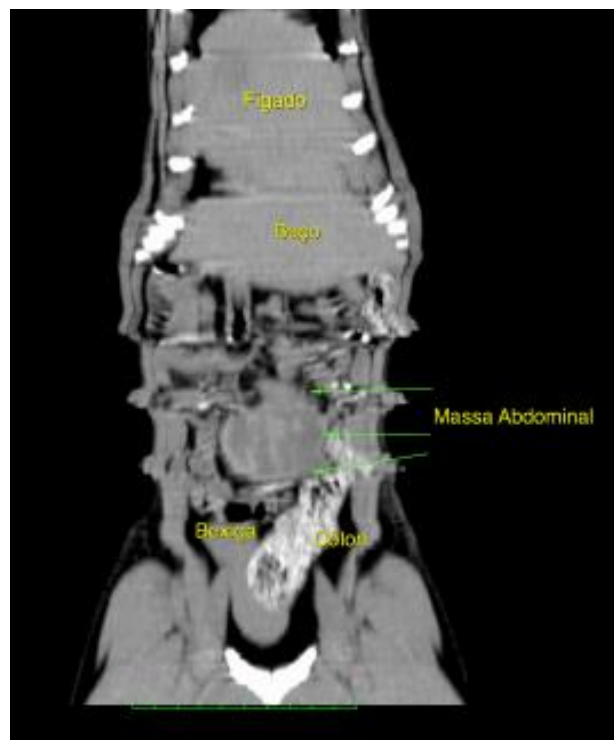


Figure 5. Computed tomographic image of a 2-year-old dog diagnosed with gossypiboma. The image shows the enlarged liver and spleen, an intra-abdominal mass, and feces in the colon.

The intra-abdominal encapsulated structure was surgically removed without complications (Figure 6). When cut, filaments indicative of gauze was visible (Figure 7).

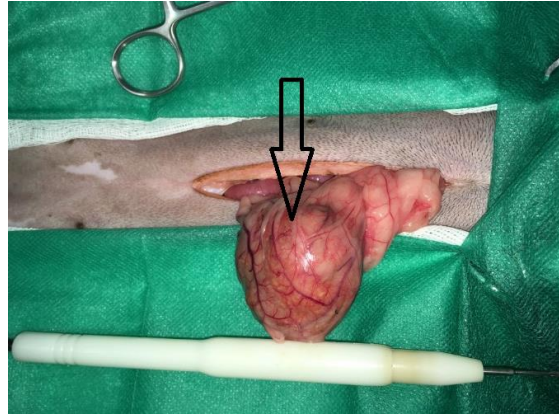


Figure 6. Photograph taken during surgery of a 2-year-old dog diagnosed with gossypiboma. The image shows an encapsulated mass (arrow), covered by omentum, that was not adhered to any organs or adjacent structures.

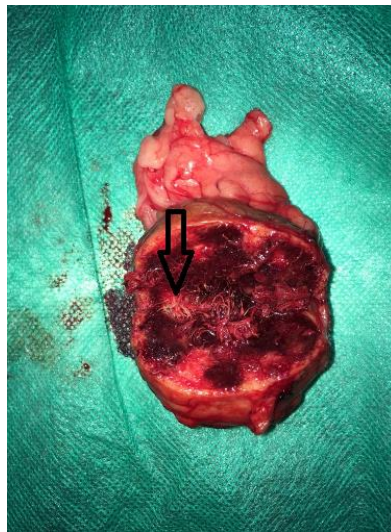


Figure 7. Photograph taken after surgery of a 2-year-old dog diagnosed with gossypiboma. The image shows the previously cut mass, with white filaments (arrow) seen at the center, which are compatible with textile material (gauze).

Macroscopic findings of the mass fixed in 10% formalin were omentum covering a white, firm nodule measuring 4.5 x 4.0 x 2.6 cm. When cut, it was red with multifocal white areas and fibers.

Histopathology findings were a nodular formation encapsulated by abundant fibrous connective tissue, with countless foamy macrophages and multinucleated foreign body cells in its interior, which delimited numerous eosinophilic filamentous structures (foreign body). It was concluded to be a moderate focal granuloma associated with the myriad of eosinophilic filamentous structures.

Discussion

Human literature has several cases of gossypiboma, but it is scarcely reported in veterinary literature. This type of event, if left untreated, may lead to serious risks to the health of the patient. Some factors related to the occurrence of gossypibomas are long surgery, failure to count initial and final number of the material, inexperience of the surgical team, among others. However, the veterinarian responsible for the mistake should be punished by the Federal Council of Veterinary Medicine according to the classification of their infraction, which is graded from minor to severe. In the present report, the owner did not make a formal complaint (DESCHAMPS; ROUX, 2009; MARQUES et al., 2014).

The suspicion of a diagnosis of gossypiboma in the present report was obtained from patient history, where the owner reported the dog had an ovariohysterectomy, as well as the presence of a circumscribed, soft, and apparently painless mass near the topography of the spleen, noticed on abdominal palpation. The differential diagnosis considered, despite the age of the patient, was splenic neoplasia (OLIVEIRA et al., 2019).

In the region where this case took place, tick diseases are endemic, and what is usually seen in these is thrombocytopenia, splenomegaly, hepatomegaly, and apathy. Clinical signs and imaging findings in the present case are compatible with recurrence of this disease. A dog that has a gossypiboma that is aseptic and non-adherent to adjacent organs or important blood vessels, as was the case here, may remain asymptomatic for a long time (CAVENAGO et al., 2015; DESCHAMPS; ROUX, 2009; OLIVEIRA et al., 2019). Because it was not possible to know for certain the cause of the clinical signs of the patient, treatment was instituted with doxycycline 10mg/Kg BID and surgery for removal of the intra-abdominal mass.

Computed tomography was helpful for surgical planning because it provided information that could not be obtained via ultrasound and conventional radiography. Suspicion of neoplasia increased after the computed tomography report suspected a neoplastic process was present. However, confirmation of the diagnosis was obtained via histopathology (AUGER et al., 2019; SILVA; SOUSA, 2013).

Conclusion

It is concluded that when the gossypiboma is aseptic and non-adherent to adjacent blood vessels and organs, as in the present report, it has a favorable prognosis. Computed tomography was essential for planning the surgery and histopathology was fundamental for a definitive diagnosis, mainly ruling out neoplasia.

Forgetting surgical material within the abdominal cavity of a patient during elective surgery is a type of medical error and the doctor responsible may suffer punishment from the Council of Veterinary Medicine.

References

AUGER, M; OLIN, S; MORANDI, F. Novel CT features of an abdominal gossypiboma in a female dog. **Case Reports in Veterinary Medicine**, article ID 2865484, 2019. Disponível em <https://www.hindawi.com/journals/crivem/2019/2865484/>.

CAVENAGO, E; CAVENAGO, A; LOURES, P; DAVID, C.S; HURTADO, D.R. Tumoração por corpo estranho – gaze: relato de caso. **Relatos de Casos Cirúrgicos**, v.0, n.2, 2015. Disponível em <https://s3-sa-east-1.amazonaws.com/publisher.gn1.com.br/relatosdocbc.org.br/pdf/n2a06.pdf>.

DESCHAMPS, J.Y.; ROUX, F.A. Extravesical textiloma (Gossypiboma) mimicking a bladder tumor in a dog. **Journal of the American Animal Hospital Association**, v.45, n.2, p.89-92, 2009. Disponível em <https://www.ncbi.nlm.nih.gov/pubmed/19258421>.

MARQUES L.M; CARLOS, R.S.A; SILVA, E.B; CLARK, R.M.O; SAPAIO, K.M.O.R; HARVEY, T.V. Imperícia e negligência em ovário-salpingohisterectomia de uma cadela – relato de caso. **Revista Brasileira de Medicina Veterinária**, v.36, n.4, p.425-429, 2014. Disponível em <https://pdfs.semanticscholar.org/78de/c49f92506e9731968a1e1f149961d4924b73.pdf>.

NETO, F.A.C; AGNOLLITTO, P.M; MAUAD, F.M; BARRETO, A.R.F; MUGILA, V.F; ELIAS JUNIOR, J. Avaliação por imagem dos gossypibomas abdominais. **Radiologia Brasileira**, v.45, n.1, 2012. Disponível em http://www.scielo.br/scielo.php?script=sci_arttext&pid=S0100-39842012000100012.

OLIVEIRA, R; MATSUI, A; RIBEIRO, J.O; SIMIONATO, G; SIMAMURA, A.C; CANOLA, J; CAMPRESI, A; VASCONCELOS, R.O; MORAES, P.C. Clinical and pathological aspects of gossypiboma in dog: case report. **Arquivo Brasileiro de Medicina Veterinária e Zootecnia**, v.71, n.1, p.102-108, 2019. Disponível em http://www.scielo.br/scielo.php?script=sci_arttext&pid=S0102-09352019000100102&lng=en&nrm=iso.

SILVA, S.M; SOUSA, J.B. Gossypiboma após operação abdominal é situação clínica desafiadora e sério problema médico legal. **ABCD - Arquivos Brasileiros de Cirurgia Digestiva**, v.26, n.2, p.140-143, 2013. Disponível em http://www.scielo.br/scielo.php?pid=S0102-67202013000200015&script=sci_abstract&tlng=pt.

Recebido em 5 de novembro de 2019

Aceito em 20 de fevereiro de 2020