



Caprine mastitis caused by *Geotrichum sp* – case report. Mastite caprina causada por *Geotrichum sp* – relato de caso.

Beatriz Alves Sague Lopez¹, [Maria das Dores Silva Araújo](#)², [Paulo Henrique Gilio Gasparotto](#)³, [João Luiz Barbosa](#)³, Alini Osowski⁴, [Jomel Francisco dos Santos](#)^{5*}, [Luiz Donizete Campeiro Junior](#)⁵

¹ Médica Veterinária – Curso de Medicina Veterinária, Centro Universitário São Lucas – JI-PARANÁ/RONDÔNIA – BRASIL.

² Zootecnista – Universidade Federal Rural de Pernambuco – UFRPE, RECIFE/PERNAMBUCO, BRASIL.

³ Docente do Curso de Medicina Veterinária – Centro Universitário São Lucas – JI-PARANÁ/RONDÔNIA – BRASIL.

⁴ Programa de Pós-Graduação em Biotecnologia Animal, Universidade Estadual Paulista “Júlio de Mesquita Filho” – BOTUCATU/SÃO PAULO, BRASIL.

⁵ Docente do Curso de Medicina Veterinária – Instituto Federal de Educação, Ciência e Tecnologia de Rondônia – IFRO – JARU/RONDÔNIA – BRASIL.

*Autor para correspondência: E-mail: jomel.santos@ifro.edu.br

Abstract

In contemporary times, mastitis occupies a prominent place for its economic and public health importance, causing direct losses on production costs and losses in milk quality. This study aimed to analyze aspects related to mycotic mastitis caused by the fungus of the genus *Geotrichum sp*. In the available literature, few reports incriminate this pathogen as the causative agent of mastitis, however, it is among the causative microorganisms. It is concluded that control and prevention measures, including environment, animal health and milking management, should be given special attention by producers, as they are measures that reduce cases of mastitis and consequently reduce costs with treatments and animal disposal.

Palavras-chave: Saúde animal. Impacto econômico. Cultura de microrganismos.

Resumo

Na contemporaneidade, a mastite ocupa lugar de destaque pela sua importância econômica e na saúde pública, causando prejuízos diretos sobre os custos de produção e perdas na qualidade do leite. Este estudo teve como objetivo analisar aspectos ligados à mastite micótica causada pelo fungo do gênero *Geotrichum sp*. Na literatura disponível, poucos relatos incriminam este patógeno como agente causador de mastite, entretanto, está entre os microrganismos causadores. Conclui-se que as medidas de controle e prevenção, incluindo ambiente, sanidade animal e manejo de ordenha devem ter atenção especial dos produtores, por serem medidas que reduzem os casos de mastite e consequentemente reduzem os custos com tratamentos e descartes de animais.

Keywords: Animal health. Economic impact. Culture of microorganisms.

Introduction

Among the diseases that affect goats, mastitis occupies a prominent place due to its economic and public health importance (ANUALPEC, 2013), and can cause great damage to dairy herds, directly impacting production costs. Milk goat farming has been increasingly developed in Brazil and has been presented in recent years as a relevant alternative for dairy activity (QUEIROGA et al., 2007). However, the success of the activity is closely linked to milk production with excellent hygiene and quality, and one of the major challenges is to have a herd free of mastitis, or at least its existence at acceptable levels (COSTA et al., 2013).

Mastitis is defined as an inflammatory reaction of the mammary gland and, according to cause or origin, can be classified as infectious, traumatic or toxic (PETRIDIS et al., 2013). Mastitis can manifest in clinical or subclinical form and the main infectious agents causing this disease are fungi, algae and bacteria, the latter being the most frequently isolated agents (ALBENZIO et al., 2012).

In small ruminants, the annual incidence of clinical episodes of fungal mastitis is estimated to be less than 5% under normal conditions. It is observed that this type of mastitis can be rare, while in endemic herds caused by bacteria it can reach incidence higher than 30% (CONTRERAS et al., 2007). Fungal mastitis occurs in the form of localized outbreaks and / or after antimicrobial treatment, the main fungi involved in mastitis are yeasts belonging to the genera *Candida sp.* and *Cryptococcus sp.*, followed by other genera such as *Geotrichum sp.*, *Pichia sp.* and *Trichosporon sp.* (VIDOTTO, 2004). Among the losses resulting from caprine mastitis, the most important are the with treatments, premature slaughter and commercial devaluation of the mothers for irreversible damage to the mammary tract of animals with high genetic lineage, deaths from gangrenous presentations and reduced milk production and changes in composition (GUARANÁ et al., 2011). Financial losses caused by mastitis occur in both clinical and subclinical form. Clinical manifestation is characterized by abnormal appearance of milk, mammary gland edema and / or systemic symptomatology of the goat (OLECHNOWICZ et al., 2014).

In Brazil there is a low number of research on the importance of caprine mastitis, so this study aims to analyze the main aspects related to mycotic mastitis caused by the fungus of the genus *Geotrichum sp.* and report a clinical case diagnosed in Ji-Paraná – RO.

Material and methods

Was attended in a private property in the municipality of Ji-Paraná – RO, a goat of approximately 3 years, Saanen breed, under the main complaint of mammary gland edema suggestive of mastitis. According to the owner, the animal had calved and soon after weaning, approximately 8 months before the date of consultation, began to present edema in the right mammary gland. Still, in an attempt to perform the treatment, the owner used several antibiotics without prescription from a veterinarian, such as gentamycin (Gentatec[®]) intramuscularly and intramammary, penicillin (Agrovet[®]) and enrofloxacin (Chemitril[®]) both intramuscularly, and of some anti-inflammatories such as dexamethasone (Dextar[®]) and flunixin meglumine (Flunamine[®]). The owner could not specify the dose of medicines used and reported that this animal had not been dewormed. The animal was kept in a paddock of approximately 210 m² composed of *Brachiaria brizantha* cv. *Marandu*, along with other goats and some sheep with ad libitum water supply, but no mineral supplementation was provided.

During the general physical examination, the animal was slightly apathetic, hypocolored mucous membranes, capillary filling time of approximately 3 seconds and slightly dehydrated. Data related to its main vital parameters are summarized in Table 1. During the physical examination of the gland, it was possible to identify significant increase in size and deformity, as shown in (Figure 1), elevated temperature, pain on palpation, presence of serous content throughout the gland and multifocal points of redness, thus characterizing classical symptomatology of inflammatory process. In addition, milking was difficult due to the presence of lumps in the milk that obstructed the roof ostium.

Table 1 - Physiological parameters found in Saanen goat

Rated Parameter	Found values	Reference values
Heart rate (bpm)	98	95 a 120
Respiratory Rate (mpm)	26	20 a 30
Ruminal movements (mov / 5min)	9	7 a 14
Temperature (° C)	39,5	38,6 a 40

bpm: beats per minute; mpm: movements per minute; ° C: celsius degrees. Source: Veterinary Semiology (FEITOSA, 2008).

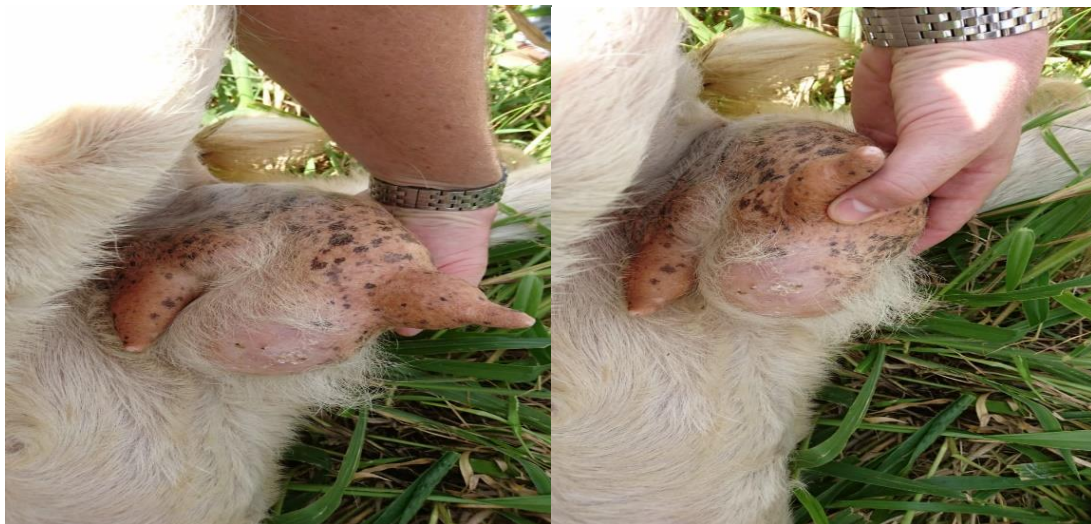

Figure 1 - Mammary gland showing characteristic signs of inflammatory process. Source: Provided by João Luiz Barbosa.

Material (milk) was then collected to diagnose the causative agent. The following procedures were used for harvesting: washing the ceilings with clean water and then drying with a gauze, followed by antiseptics of the roof ostium with 70% alcohol and samples taken from sterile plastic bottles. Then sent to the Microbiology Laboratory - Veterinary Hospital, under refrigeration, in an isothermal box containing recyclable ice.

For the microbiological tests, the microorganisms were transferred to broth brain-heart (BHI) medium to enrich the bacteria. After enrichment, there was no bacterial growth, so we opted for the fungal diagnosis. To perform the fungal diagnosis, the samples were incubated from 25° C to 27° C for 15 days in a greenhouse DBO (Biochemical Oxygen Demand). After incubation, the macro and microscopic morphological characteristics were evaluated (Figure 2). The fungus was isolated from the obtained sample, where it was subjected to the following procedures: homogenization and dilution

in sabouraud-dextrose agar with chloramphenicol. This means diluting the components with 100 mg chloramphenicol in 10 mL 95° C alcohol. It is necessary to add in 1 liter of agar sabourand dextrose (ASD) before sterilization: distilled water and adjust pH to 5.6 and heat to complete dissolution, then distribute about 10 mL per tube and autoclave at 120 ° C for 15 minutes.

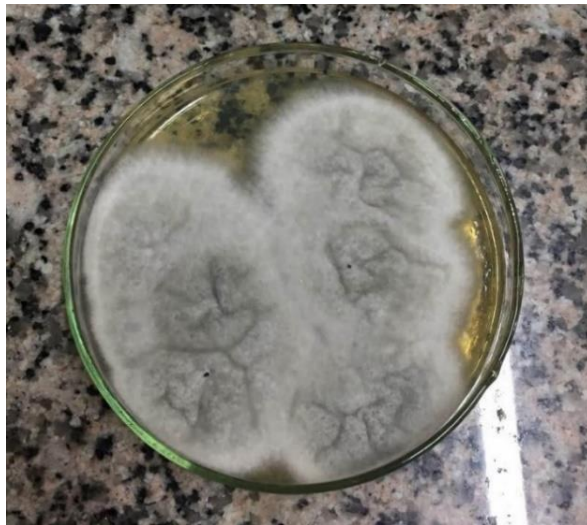

Figure 2 - Microbiological examination for fungal growth. Source: Veterinary Microbiology Laboratory of São Lucas College.

After initial screening that allowed the separation of yeast from filamentous fungi, they were submitted to biochemical and physiological tests, such as microculture in CornMeal medium to verify pseudohypha, chlamydoconid and blastoconid production, germ tube test and other complementary tests (Figure 3). For the identification of the resulting colonies, in the morphological microscopic analyzes, slides were prepared using lactofenol blue or clarifying cotton (sodium hydroxide - 20% noth in aqueous solution) (Figure 4).



Figure 3 - Germ Tube Cultivation. Source: Veterinary Microbiology Laboratory of São Lucas College.

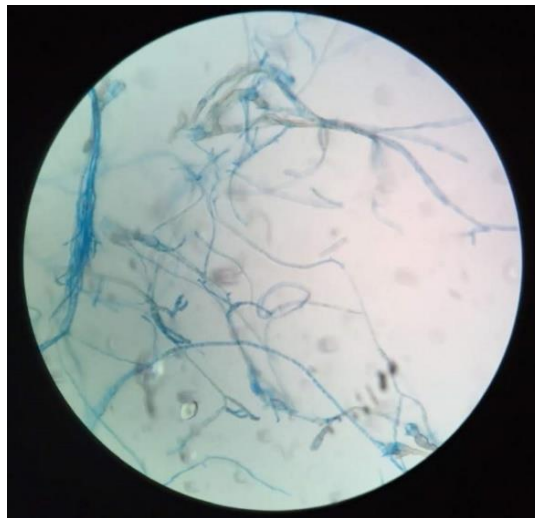


Figure 4 - Morphological Microscopic Analysis.
Source: Veterinary Microbiology Laboratory of São Lucas College.

Results and discussion

The case in question drew attention because it is rare in our region for two reasons: it is a goat mastitis and because it is fungal in origin, being the only one reported with this etiology within the herd, corroborating Langoni et al. (2017), who state that mastitis occurs mainly in the form of outbreaks or as isolated cases in both clinical and subclinical form. During the general physical examination, the animal presented classic symptoms of mastitis, such as elevated udder temperature, pain on palpation, presence of serous content throughout the gland and multifocal points of redness, symptoms also found in reports such as de Benedette et al. (2008) and Tozzetti et al. (2008).

Unlike the above authors, in our case, we found changes in behavior and loss of appetite of the animal. Tomazi and Santos (2015) mention that the symptoms may vary from mild (with inflammatory signs in the mammary gland) to acute, with systemic signs such as rumen stasis, dehydration, shock, and even death of the affected animal. It is known that the mastitis of this case started after weaning, corroborating with Veiga (2016) who states that the rate of new cases of mastitis is higher during the dry period than during lactation. Environmental agents such as this report usually cause infections acquired during the dry season, and some of these infections persist during the next lactation.

During diagnosis, as most mastitis is bacterial, as stated by Blagitz et al. (2010), the growth of such microorganisms was expected, but again the result of the cultivation was surprising, because there was no growth of bacteria, but a white, velvety and dry colony characteristic of fungal growth, confirming the negative result for bacteria, and thus justifying the failure of the antibiotic treatment used by the owner of the animal prior to care. After the initial screening that allowed the separation of yeast from filamentous fungi, these microorganisms were submitted to biochemical and physiological tests to identify the species to be studied. Finally, morphological microscopic analyzes were performed to identify the colonies, and found fungi of the genus *Geotrichum sp.*

Langoni et al. (2017) isolated milk samples in sheep blood agar medium for identification of organisms causing bovine mastitis, this medium is used for bacterial growth and there was fungal growth of the genus *Geotrichum candidum*. Already Lima et al. (2020) and Correa et al. (2010) used this same culture medium to identify bacterial agents in goat mastitis. Unlike the above-mentioned

authors, in the case reported here, the culture medium used was sabouraud-dextrose agar with chloramphenicol, characteristic for fungal cultivation, as indicated by Gava (2002).

According to researcher Amorim (2012), *Geotrichum sp.* is an opportunistic yeast fungus widely distributed in nature, such as soil, forage and other places, but can cause ringworm in animals and humans. Araújo (2009) discusses the same stating that it is a fungus found in the human microbiota and can cause geotrichosis, a disease that primarily affects the lungs, but only in highly immunocompromised hosts. According to Langoni et al. (2017) the etiological agents of these mastitis types are very rare and diverse. Yeasts are an important part of the microflora of dairy products and are generally detected in large counts in milk and milk derivatives due to their richness of proteins, lipids, sugars and organic acids. Cruz (2017) states that this type of fungus may be beneficial to the food industry as it grows in cheese, protecting the growth of other fungi and producing some enzymes that change the appearance of cheese, making it more wrinkled and more tasty.

In turn, this microorganism causes environmental type mastitis and can be spread from infected goats to healthy goats during close contact between animals (PEIXOTO et al., 2010). In the available literature there are few reports incriminating this pathogen as a causative agent of mastitis. However, despite its low occurrence, it is among the microorganisms that cause subclinical and clinical mastitis. According to Veludo (2018), this occurrence is mainly due to poor hygiene and sanitary methods used in the handling of the animal, so as prevention it is necessary to attend the basic procedures during milking and production, as well as care in the distribution network. and in consumption.

After the discovery of the mastitis-causing pathogen of the reported case, the property was returned to inform the results of the exams and to apply the therapeutic protocol with antifungals for the treatment of the animal, the base of miconazole, cephalixin, neomycin and prednisolone (Vetimast Plus VL[®]) associated with the systemic treatment of amphotericin B together with ketoconazole. However, the gland was highly compromised by the disease, to an irreversible degree to the therapeutic treatment, being recommended the surgical treatment for the complete cure of the animal. Hagiwara (2002) state that the successful treatment of these infections depends on the identification of the species and the pattern of antifungal sensitivity.

According to Oliveira and Medeiros (2015) the use of antimicrobials for an extended period is pointed as the main factor that favors the occurrence of mycotic mastitis, as it affects the animal's indigenous microbiota, since when in balance, they act as a natural defense of the animal, a fact which emphasizes the importance of implementing proper management to prevent infection, which may have helped to reach the clinical picture presented by the animal. Therefore, a rapid and specific diagnosis is fundamental for the early introduction of adequate therapy, and it is important to develop more practical, economical and easy to use identification methods.

Conclusion

Mastitis in ruminants is a subject that has been much investigated, however research on mastitis in goats is scarce or incomplete. According to the data obtained in this work, it is found that the fungus *Geotrichum sp.* is not as prevalent as an etiological agent of goat mastitis. The diagnosis of the disease occurred through characteristic clinical signs of mastitis and the identification of the fungus. It is important to emphasize to dairy farmers methods of intramammary and systemic treatment, as well as control and prevention measures, including environment, animal health and

milking management, as they are the main risk factors identified in cases of mastitis, reducing treatment costs, animal discards.

Interest conflicts

There was no conflict of interest of the authors.

Authors' contribution

Beatriz Alves Sague Lopez - original idea, reading and interpretation of the works, writing and guidance; Paulo Henrique Gilio Gasparotto, João Luiz Barbosa and Alini Osowski - writing and corrections; Maria das Dores Silva Araújo, Jomel Francisco dos Santos and Luiz Donizete Campeiro Junior - guidance, corrections and text revision.

References

- ALBENZIO, M.; SANTILLO, A.; CAROPRESE, M.; RUGGIERI, D.; CILIBERTI, M.; SEVI, A. Immune competence of the mammary gland as affected by somatic cell and pathogenic bacteria in ewes with subclinical mastitis. **Journal of Dairy Science**, v. 95, p. 3877-3887, 2012. <https://doi.org/10.3168/jds.2012-5357>
- AMORIM, G. K. de S. **Identificação da microbiota fúngica da carne moída comercializada no mercado central de Campina Grande – PB**. 50f. Trabalho de Conclusão de Curso (Graduação em Ciências Biológicas) – Universidade Estadual da Paraíba, Campina Grande, 2012. <http://dspace.bc.uepb.edu.br/jspui/handle/123456789/4185>
- ANUALPEC. **Anuário da Pecuária Brasileira**. São Paulo: FNP Consultoria e Agroinformativos, 2013, 357p.
- ARAÚJO, F. C. A. **Atlas de Auxílio às Aulas Práticas em Micologia**. Cadastro PROAC n.º 487. Universidade Federal Fluminense, Niterói, 2009. <https://www.docsity.com/pt/atlas-de-auxilio-as-aulas-praticas-de-micologia/4765694/>
- BENEDETTE, M. F.; SILVA, D.; ROCHA, F. P. C.; SANTOS, D. A. N.; COSTA, E. A. D´A.; AVANZA, M. F. B. Bovine mastitis. **Revista Científica Eletrônica de Medicina Veterinária**, v. 6, n. 11, 2008. http://faef.revista.inf.br/imagens_arquivos/arquivos_destaque/s8Qkxdp3ibXOROS_2013-6-13-15-52-55.pdf
- BLAGITZ, M. G.; BATISTA, C. F.; NUNES, G. R.; SOUZA, F. N.; GOMES, V.; AZEDO, M. R.; SUCUPIRA, M. C. A.; LIBERA, A. M. M. P. D. The physico-chemical, cellular and microbiological characteristics of mammary gland secretions of Santa Inês ewes during lactation and after weaning. **Revista de Ciências Agrárias**, v. 53, n. 2, p. 137-142, 2010. <https://doi.org/10.4322/rca.2011.019>
- CONTRERAS, A.; SIERRA, D.; SÁNCHEZ, A.; CORRALES, J. C.; MARCO, J. C.; PAAPE, M. J.; GONZALO, C. Mastitis in small ruminants. **Small Ruminant Research**, v. 68, n. 1/2, p. 145-153, 2007. <https://doi.org/10.1016/j.smallrumres.2006.09.011>
- CORREA, C. M.; MICHAELSEN, R.; RIBEIRO, M. E. R.; PINTO, A. T.; ZANELA, M. B.; SCHMIDT, V. Milk composition and mastitis diagnosis in goats. **Acta Scientiae Veterinariae**, v. 38, n. 3, p. 273-278, 2010. <https://doi.org/10.22456/1679-9216.17063>
- COSTA, C. R. M.; FEITOSA, M. L. T.; PESSOA, G. T.; BEZERRA, D. O.; FERRAZ, M. S.; CARVALHO, M. A. M. Caprine mastitis: etiology and epidemiology: literature Review. **PUBVET**, v. 7, n. 8, p. 619-706, 2013. <https://www.pubvet.com.br/artigo/594/mastite-caprina-etilogia-e-epidemiologia-revisatildeo-de-literatura>

- CRUZ, L. **Cientistas explicam mofo no Queijo Minas Artesanal**. 2017. <https://www.milkpoint.com.br/noticias-e-mercado/giro-noticias/cientistas-explicam-mofo-no-queijo-minas-artesanal-106852n.aspx>
- FEITOSA, F. L. F. **Semiologia Veterinária: a arte do diagnóstico**. 2ª ed. São Paulo: Roca, 2008, 752p.
- GAVA, M. A. **Desempenho de diferentes meios de cultura utilizados na avaliação de fungos presentes em ambientes de produção de alimentos**. 50p. Dissertação (Mestrado) – Escola Superior de Agricultura Luiz de Queiroz, Universidade de São Paulo, Piracicaba – SP, 2002. <https://www.teses.usp.br/teses/disponiveis/11/11138/tde-12082002-144728/pt-br.php>
- GUARANÁ, E. L. S.; SANTOS, R. A.; CAMPOS, A. G. S. S.; SILVA, N. S.; AFONSO, J. A. B.; MENDONÇA, C. L. Cellular dynamics and microbiological of milk of Santa Inês ewes accompanied during lactation. **Pesquisa Veterinária Brasileira**, v. 31, n. 10, p. 851-858, 2011. <https://doi.org/10.1590/S0100-736X2011001000004>
- HAGIWARA, M. K. Clínica veterinária: um tratado de doenças dos bovinos, ovinos, suínos, caprinos e equinos. **Veterinary Medicine**. 9ª ed. Rio de Janeiro: Guanabara Koogan, 2002.
- LANGONI, H.; SALINA, A.; OLIVEIRA, G. C.; JUNQUEIRA, N. B.; MENOZZI, B. D.; JOAQUIM, S. F. Considerations on the treatment of mastitis. **Pesquisa Veterinária Brasileira**, v. 37, n. 11, p.1261-1269, 2017. <https://doi.org/10.1590/S0100-736X2017001100011>
- LIMA, M. C.; BARROS, M.; SCATAMBURLO, T. M.; POLVEIRO, R. C.; CASTRO, L. K.; GUIMARÃES, S. H. S.; COSTA, S. L.; COSTA, M. M.; MOREIRA, M. A. S. Profiles of *Staphylococcus aureus* isolated from goat persistent mastitis before and after treatment with enrofloxacin. **BMC Microbiology**, v. 20, p. 1-11, 2020. <https://doi.org/10.1186/s12866-020-01793-9>
- OLECHNOWICZ, J.; JAŚKOWSKI, J. M. Mastitis in small ruminants. **Medycyna Weterynaryjna**, v. 70, n. 2, p. 67-72, 2014. https://www.researchgate.net/publication/259969131_Mastitis_in_small_ruminants
- OLIVEIRA, M. R. M.; MEDEIROS, M. Agentes causadores de mastite e resistência bacteriana. **Revista Científica de Medicina Veterinária da FACIPLAC**, v. 2, n. 1, p. 45-60, 2015. <https://1library.org/document/yee54j1y-agentes-causadores-de-mastite-e-resistencia-bacteriana.html>
- PEIXOTO, R. M.; MOTA, R. A.; COSTA, M. M. Small ruminant mastitis in Brazil. **Pesquisa Veterinária Brasileira**, v. 30, n. 9, p. 754-762, 2010. <https://doi.org/10.1590/S0100-736X2010000900008>
- PETRIDIS, I. G.; MAVROGIANNI, V. S.; FRAGKOU, I. A.; GOUGOULIS, D. A.; TZORA, A.; FOTOU, K.; SKOUFOS, I.; AMIRIDIS, G. S.; BROZOS, C.; FTHENAKIS, G. C. Effects of drying-off procedure of ewes' udder in subsequent mammary infection and development of mastitis. **Small Ruminant Research**, v. 110, n. 2/3, p. 128-132, 2013. <https://doi.org/10.1016/j.smallrumres.2012.11.020>
- QUEIROGA, R. C. R. E.; COSTA, R. G.; BISCONTINI, T. M. B.; MEDEIROS, A. N.; MADRUGA, M. S.; SCHULER, A. R. P. Effects of flock management, milking sanitary conditions and lactation stage on milk composition of Saanen goats. **Revista Brasileira de Zootecnia**, v. 36, n. 2, p. 430-437, 2007. <https://doi.org/10.1590/S1516-35982007000200021>
- TOMAZI, T.; SANTOS, V. M. **Prejuízos de longo prazo da mastite clínica causada por *Escherichia coli***. 2015. <https://www.milkpoint.com.br/colunas/marco-veiga-dos-santos/prejuizos-de-longo-prazo-da-mastite-clinica-causada-por-escherichia-coli-205758n.aspx>
- TOZZETTI, D. S.; BATAIER, M. B. N.; ALMEIDA, L. R.; PICCININ, A. Prevention, control and treatment of bovine mastitis – literature review. **Revista Científica Eletrônica de Medicina Veterinária**, v. 6, n. 10, p. 1-7, 2008. http://www.faeF.revista.inf.br/imagens_arquivos/arquivos_destaque/YFbjMNRGCotOL73_2013-5-28-15-25-40.pdf

VEIGA, M. **Controle de mastite no período seco.** 2016. Disponível em: <https://www.milkpoint.com.br/empresas/novidades-parceiros/controle-de-mastite-no-periodo-seco-100738n.aspx>

VELUDO, A. F. **O Efeito da Raça, Idade, Número de Partos e Fase da Lactação na Incidência de Mastites Clínicas em Caprinos Leiteiros.** 60p. Tese (Doutorado) – Faculdade de Medicina Veterinária, Universidade de Lisboa, Portugal, 2018. <https://1library.org/document/q2m87p2y-numero-partos-lactacao-incidencia-mastites-clinicas-caprinos-leiteiros.html#fulltext-content>

VIDOTTO, V.; PONTÓN, J.; AOKI, S.; QUINDÓS, G.; MANTOAN, B.; PUGLIESE, A.; ITO-KUWA, S.; NAKAMURA, K. Differences in extracellular enzymatic activity between *Candida dubliniensis* and *Candida albicans* isolates. **Revista Iberoamericana de Micologia**, v. 21, n. 2, p. 70-74, 2004. <https://www.reviberoammicol.com/2004-21/070074.pdf>

Recebido em 6 de novembro de 2022
Retornado para ajustes em 25 de janeiro de 2023
Recebido com ajustes em 26 de fevereiro de 2023
Aceito em 27 de fevereiro de 2023